Deep Peroneal Motor

Electromyograph Instrument Parameters:

Filter Settings/Frequency Response: 10 Hz - 10,000 Hz
Sweep Speed: 2 - 5 milliseconds/Division
Sensitivity/Gain: 500 - 2,000 microvolts/Division

Patient Position: (Illustration 13) The patient is positioned in a comfortable, relaxed sidelying position facing away from the examiner. The hip and knee are slightly flexed with the ankle in a neutral position. A single pillow should be placed between the patient's knees for comfort and to support the limb being examined.

Electrode Placement: (Illustration 13)

Active (Recording) Electrode: The active recording electrode is positioned over the anatomic center of the extensor digitorum brevis muscle in the anterior, lateral aspect of the proximal midtarsal area of the foot.

Reference Electrode: The reference electrode is placed off the extensor digitorum brevis muscle on the little (5th) toe.

Ground Electrode: The ground should be positioned on the lateral or medial malleolus between the active and stimulating electrodes.

Electrostimulation: (Illustration 14)

Percutaneous electrostimulation is performed at the appropriate anatomic sites in the following order:

S1: The nerve is stimulated initially below the head of the fibula and anterior to the neck of the fibula. The stimulator should be positioned along the anatomic course of the nerve around the neck of the fibula.

S2: Distal stimulation is applied at the anterior ankle, proximal to the center of the active electrode located on the extensor digitorum brevis muscle. The distal site at the anterior ankle is between the extensor digitorum longus and extensor hallucis longus tendons. (See Illustration 21, Distal Lower Extremity Stimulation Sites)

S3: The popliteal space stimulation site is not less than 10 cm proximal to the fibular neck site. The peroneal nerve is located in the lateral border of the popliteal space, near the biceps femoris.

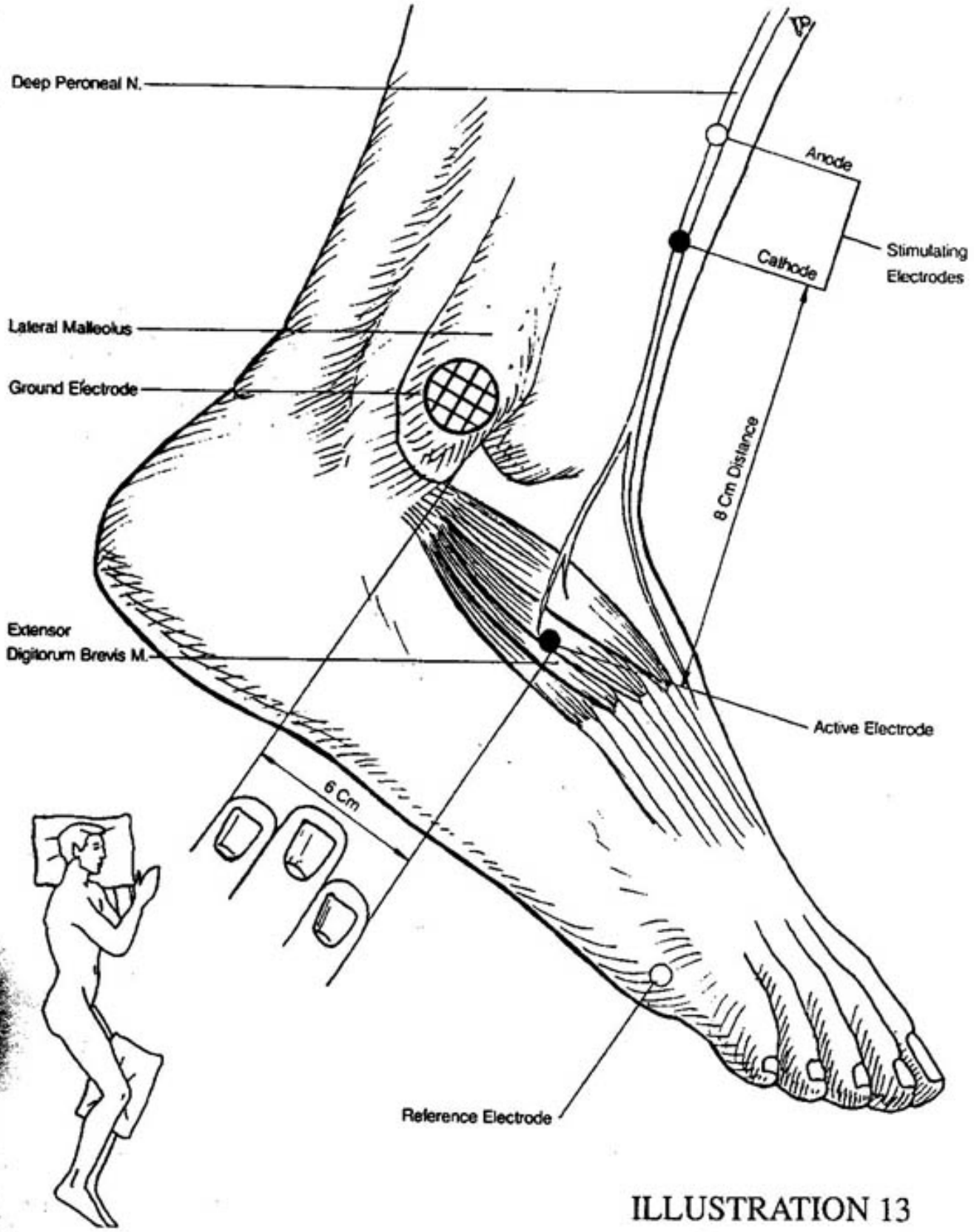

ILLUSTRATION 13

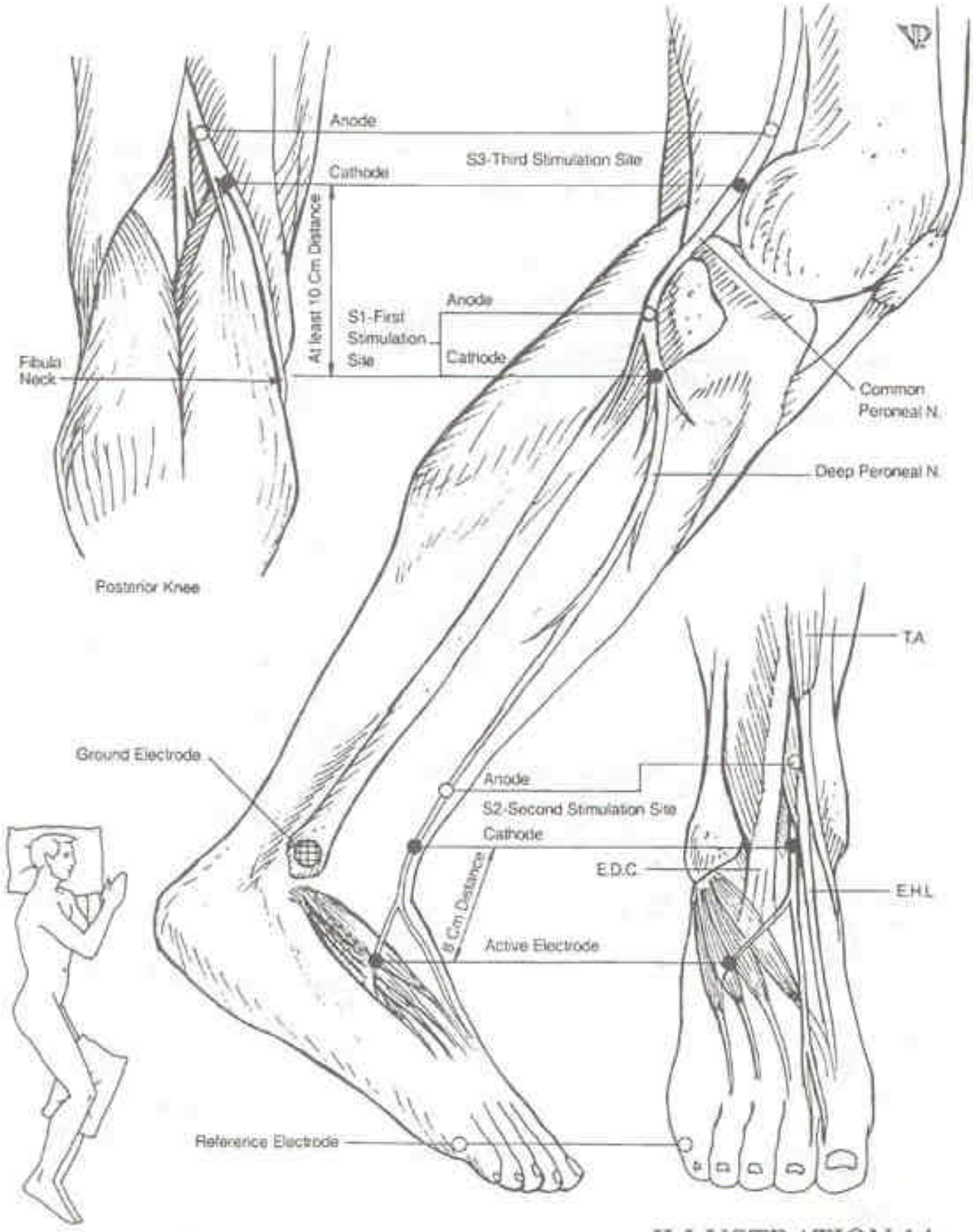

ILLUSTRATION 14

TECHNICAL COMMENTS:

Evoked muscle action potential responses from all three sites **should** be similar in waveform, amplitude, and duration of response.

When applying proximal stimulation in the popliteal fossa the clinical response in the leg/calf should be monitored to avoid volume conducted stimulation of the posterior tibial nerve. Ankle **eversion** ensures that the peroneal nerve is being stimulated while plantar flexion of the ankle indicates stimulation of the tibial nerve.

Distal stimulation is performed approximately halfway between the malleoli, lateral to the extensor hallucis longus tendon, just proximal to the level of the anterior tarsal tunnel. Occasionally the response may be improved by stimulating more laterally to the extensor digitorum longus tendon. In obese patients, or in patients with edema or induration, the ankle response may be difficult to elicit. Increasing the stimulus intensity and/or pulse width duration may overcome this difficulty.